

# INTERNATIONAL JOURNAL OF MULTIDISCIPLINARY: APPLIED BUSINESS AND EDUCATION RESEARCH

2022, Vol. 3, No. 8, 1583 – 1588

<http://dx.doi.org/10.11594/ijmaber.03.08.21>

---

## Research Article

### Radiography of the Paranasal Sinus with Maxial Sinusitis in North Sumatra-Medan University Hospital

Juliana Lasniar Sidauruk\*, Liberti Tarigan

Academic Radiodiagnostic Techniques and Radiotherapy (ATRO), Yayasan Sinar Amal Bhakti Medan, Indonesia

---

#### Article history:

Submission August 2022

Revised August 2022

Accepted August 2022

#### \*Corresponding author:

E-mail:

[julianasidauruk75@gmail.com](mailto:julianasidauruk75@gmail.com)

#### ABSTRACT

Paranasal sinus radiography is an appropriate method for showing abnormalities in the paranasal sinuses and showing abnormalities in suspected Maxillary Sinusitis. The purpose of this examination is to determine the location and location of sinusitis by obtaining an optimal picture with radiographic examination of the paranasal sinuses. This research was conducted at the Radiology Installation of the University of North Sumatra-Medan Hospital. Using a general X-ray unit with an aircraft capacity of 1100 mA in February 2022 - May 2022, with a qualitative descriptive research type. To show the anatomical description and pathological abnormalities in the paranasal sinuses, especially maxillary sinuses, parietoacanthia (water's method) and lateral projections are used. The results of the examination showed that there was Sinusitis Maxillaris Sinistra and a suspected Sinusitis Ethmoidalis Sinistra.

**Keywords:** *Digital Radiography (DR), Fraktur, Shoulder Joint*

---

#### Introduction

The paranasal sinuses are air-filled cavities lined by a mucous membrane that surrounds the nasal cavity. As for the paranasal sinuses divided into four groups according to the location of the bone, namely maxillary sinuses, frontal sinuses, ethmoidal sinuses and sinuses sphenoidalis. According to Cappello et al. (2018) Since The maxillary sinus is a pair of sinuses that has the largest structure located anteriorly and is part of the facial bone while the frontal sinuses are located between the inside and out-

side of the skull, the ethmoidal sinuses are located within the ethmoid bone, and the sphenoidal sinuses are located in the sphenoid and posterior bones. The ethmoidal sinus is part of the cranium (Y. Kim et al., 2019; Jeon et al., 2021). The paranasal sinuses, according to Murata et al. (2019), have functions such as a sound resonance chamber, lighten head weight, help warm and humidify inhaled air, act as vibration dampers, and play a role in controlling the immune system. According to Little et al. (2018) the paranasal sinuses have several

---

#### How to cite:

Sidauruk, J. L. & Tarigan, L. (2022). Radiography of the Paranasal Sinus with Maxial Sinusitis in North Sumatra-Medan University Hospital. *International Journal of Multidisciplinary: Applied Business and Education Research*. 3 (8), 1583 – 1588. doi: 10.11594/ijmaber.03.08.21

indications such as polyps and one of the most frequently encountered is sinusitis.

Based on data from the Ministry of Health of the Republic of Indonesia in 2003 (Idugboe et al., 2018), it was stated that nasal and sinus disease was ranked 25th out of 50 major disease patterns or about 102,817 outpatients in hospitals (Huang et al., 2019). Sinusitis is an infection of the sinus mucosa and can be categorized as acute or chronic sinusitis. Patients with sinusitis will feel headache, pain, swelling around the infected sinus and accompanied by low-grade fever (Terlemez et al., 2019). To establish the diagnosis in patients with sinusitis can be done through radiological examination of the paranasal sinuses. In the examination of the paranasal sinuses, there are several projections used in the examination of the paranasal sinuses, namely, the postero anterior (PA) projection of the Caldwell method to show the frontal sinus, and the ethmoidal sinus from the anterior aspect (H.-G. Kim et al., 2019). The second projection is lateral facebone to show the four sinuses from the lateral side (frontal sinus, maxillary sinus, ethmoid sinus and sphenoid sinus). The third projection is the parietoacanthial Water's Closed Mouth method to show the maxillary and frontal sinuses (Dave et al., 2020). In addition there are two additional projections in the examination of the paranasal sinuses, including the submentovertex projection to show the ethmoidal and sphenoidal sinuses. And the parietoacanthial projection of the Water's Open Mouth method to show the maxillary sinus, frontal sinus and sphenoid sinus (Sheikh et al., 2018).

In accordance with the cases raised in the diagnosis of maxillary sinusitis, the authors will discuss more about the appropriate radiographic technique (Lim et al., 2022; Starkey & Mortman, 2019). In connection with the background of the problem and the scope of the radiography of the paranasal sinuses with suspected Maxillary Sinusitis, the authors formulate the problem that arises is "How are the efforts made to obtain the results of radiographs of the paranasal sinuses with the suspicion of optimal Maxillary Sinusitis? at the University of North Sumatra-Medan Hospital?" The purpose of this study was to find out how the process of examining the paranasal sinuses suspected of

maxillary sinusitis at the University of North Sumatra-Medan Hospital (Kuwana et al., 2021). And the second is to find out the right radiographic technique to produce an optimal picture on radiographic examination of the paranasal sinuses suspected of maxillary sinusitis (Al Qahtani, 2019). And the third is to find out the results of the radiographic examination of the paranasal sinuses with a suspicion of maxillary sinusitis. And the last one can show the anatomy and abnormalities of the paranasal sinuses, especially with clinical maxillary sinusitis (Fenner et al., 2019).

## Methods

Research on *paranasal sinus radiography* with cases of *maxillary sinusitis* uses qualitative research (Zhou et al., 2021). The data collection technique is based on the results of observations and interviews. Qualitative research techniques are research on descriptive research and tend to use analysis and the perspective of the subject is more highlighted. In this research, the theoretical basis is used as a guide so that the research focus is in accordance with the facts in the field and the theoretical basis is also useful for providing an overview of the research background and as a material for discussing research results (Shrestha et al., 2020).

## Research Time and Place

Research Place : Radiology Installation, University of North Sumatra Hospital  
Research Time : 03 February 2022 – May 2022

## Data collection technique

To obtain data correctly and accurately in the preparation of this paper, the author uses several methods such as the following.

1. Learning experience during lectures  
By applying the knowledge gained during lectures and clinical practice experience.
2. Observation  
Namely, the author observed the radiographic examination of the *paranasal sinuses* carried out on patients at the Radiology Installation of the University of North Sumatra Hospital.
3. Documentation  
Namely, the authors recorded and documented the course of examination of the

*paranasal sinuses* with suspected *maxillary sinusitis* from the beginning of the examination until the examination was completed.

#### 4. Interview

That is by doing to the patient's family in terms of the patient's illness. Conduct discussions and cooperation with radiographers, and consult with radiology specialists (Mori et al., 2021).

### Result Analysis

The data collected is processed, then connected to the hypothesis and then get a conclusion (Serindere & Aktuna Belgin, 2020). In the results of the radiographic image of the *paranasal sinuses* with a suspicion of *maxillary sinusitis* using the basic projection, namely the *parietoacanthia projection (Water's method)* and lateral projection. The aircraft used is a PHILIPS brand general X-ray unit with a capacity of 1100 mA. Processing film using CR and the results are optimal.

### Results and Discussion

The case selected by the author is a radiographic examination of the paranasal sinuses suspected of having maxillary sinusitis at the Radiology Installation of the University of North Sumatra Hospital.

The following is the data taken:

#### 1. Patient Identification

Name	: Mr. S
Gender	: Male
Age	: 37 years
Temporary diagnosis	: Sinusitis
Photo Request	: Paranasal sinuses
Examination Date	: May 16, 2022

#### 2. Implementation Procedures at the University of North Sumatra Hospital Reading Photo Request Letter

The radiographer officer reads the request letter for radiological examination to be carried out, especially a temporary clinical diagnosis from the sending doctor who requested a radiological examination of the Paranasal Sinus with cases of maxillary sinusitis which was carried out at the University Hospital of North Sumatra.

#### 3. Patient Preparation

On examination of the paranasal sinuses with suspected maxillary sinusitis, there is no special preparation. However, prior to the examination, the radiographer must remove jewelry such as earrings, necklaces and other accessories in the head and neck area so as not to interfere with the results of the image and the radiographer must explain the examination procedure to the patient and/or his accompanying family.

#### 4. Preparation of Tools and Materials

Before the radiographic examination is carried out, first the X-ray machine is heated so that the components on the X-ray machine can work optimally, then proceed with adjusting the shooting conditions. The X-ray unit used in this examination is a general X-ray unit at the University of North Sumatra Hospital with the following specifications:

X-Ray Aircraft Brand	: Philips
Airplane Type	: Velara
Series Number	: 10140193
Aircraft Capacity	: 1100 mA
Aircraft Services	: Radiography and Fluoroscopy

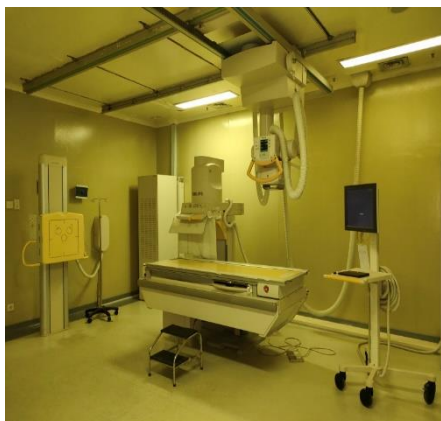


Figure 1. PHILIPS X-Ray at the University of North Sumatra Hospital

Before the inspection is carried out, the X-ray machine is turned on by first controlling the incoming voltage to the PLN on the line voltage meter, adjusting the lighting conditions according to the object to be photographed.

#### 1. X-ray film

The size of the film used for this examination is a film measuring 24cm x 30cm with parietoacanthia (water's method) and lateral projections.

#### 2. Cassette

The cassette used is the Carestream-Cassette and Screen PQ for CR brand with a size of 24 cm x 30 cm.

#### 3. Marker

The marker (code) is made of Pb. For L code, patient name, examination date, gender.

#### 4. Patient preparation.

In this examination, the patient does not do any special preparation, the patient only needs to remove the earrings and other accessories that are in the head and neck area. In this examination, a chair is required and the patient is placed in an upright position facing the bucky stand.

#### 5. Position Setting

The projections made by the author are adjusted to the limitations described on the previous page, to perform an examination of the paranasal sinuses in a patient named Mr.

S with the suspicion of maxillary sinusitis, two projections were performed, namely the parietoacanthial (water's method) and lateral projections according to the patient's diagnostic needs.

#### 6. Examination Technique

The projections used in this research are as follows:

##### 1. Parietoachantial projection (Water's method)

- Purpose of Examination: To show the maxillary sinus
- Patient Position : Position the patient sitting upright, facing the bucky stand. The head is made up so that the chin area is attached to the bucky.
- Object Position : Adjust the head so that the Mento Meatal Line is perpendicular to the film and the Orbito Meatal Line forms an angle of 37° to the plane of the film.
- Focus Film Distance : 100 cm
- Central Ray : Horizontal, perpendicular to the cassette.
- Central Point : right on Parieto Occipital through Acanthion.
- Film/cassette : 24 x 30 cm
- Shooting Condition : 81 kV , 14 mAs
- Evaluation : Appearance of the maxillary sinus, ethmoidal sinus and sphenoid sinus.

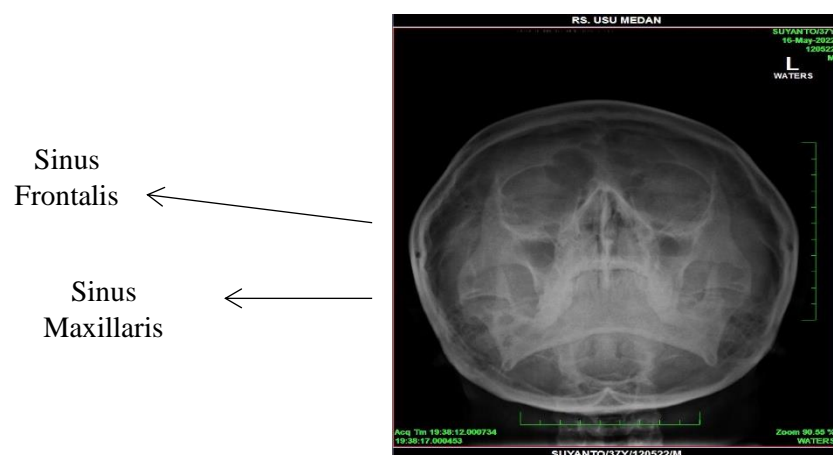


Figure 2. Paranasal Sinus Radiography Parietoacanthial (Waters) projection

#### 2. Lateral Projection

- Purpose of examination : To show abnormalities in the paranasal sinuses from the lateral side.
- Patient Position : Position the patient with the left side of the body attached to the bucky stand (LAO), so

that the head can be adjusted true laterally.

- Object Position : Position the left side of the head against the cassette. Set the Infraorbitomeatal Line parallel to the plane of the film. Adjust the chin so that the Interpupillary Line is perpendicular to the plane of the film.
- Focus Film Distance : 100 cm
- Central Ray : Horizontal

- Central Point : about 1.3 cm – 2.5 cm at the posterior outer canthus
- Film/cassette : 24 cm × 30 cm
- Shooting Conditions : 81 kV, 12.5 mAs
- Evaluation : Looks like the frontal sinus, the covered maxillary sinus and the sphenoid sinus from the lateral side . The ethmoidal sinuses are visible but not clear because they are not true lateral.

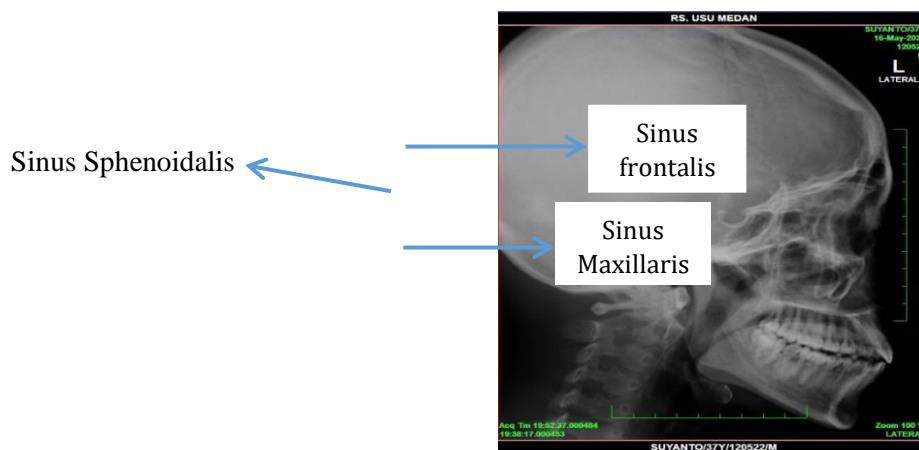


Figure 3. Radiography of the Paranasal Sinuses Lateral Projection

7. Expertise results (Original Sheet is attached in the Appendix)

Paranasal Sinus X-Ray Examination Results: There was a clouding in the left maxillary sinus with suspicion of a clouding in the left ethmoidal sinus.

The bones of the sinus wall are intact. No lytic, blastic or destructive lesions were seen. Septum of rice in the middle. The nasal conchae are not hypertrophied.

Conclusion: maxillary sinusitis and suspected left ethmoidal sinusitis.

## Conclusion

After doing a radiographic examination of the paranasal sinuses suspected of maxillary sinusitis at the University of North Sumatra Hospital, the authors provide the following conclusions and suggestions: In radiography of the paranasal sinuses with suspected maxillary sinusitis, good cooperation between the patient/patient's family and the radiographer is essential. The use of parietoacanthia (Water's method) and lateral projections have been able

to show the patient's left maxillary sinusitis . On radiographic examination of the paranasal sinuses with suspicion of maxillary sinusitis at the Radiology installation of the University of North Sumatra Hospital using Computer Radiography , it can minimize photo repetition and the amount of radiation received by the patient.

## References

- Al Qahtani, F. (2019). Diagnostic accuracy of digital paranasal sinus view and computed tomography in the evaluation of maxillary sinusitis–A comparative study. *IP International Journal of Maxillofacial Imaging*, 5(1), 3–9.
- Cappello, Z. J., Minutello, K., & Dublin, A. B. (2018). *Anatomy, head and neck, nose paranasal sinuses*.
- Dave, M., Loughlin, A., Walker, E., & Davies, J. (2020). Challenges in plain film radiographic diagnosis for the dental team: a review of the maxillary sinus. *British Dental Journal*, 228(8), 587–594.
- Fenner, M. F., Verwilghen, D., Townsend, N., Simhofer, H., Schwarzer, J., Zani, D. D., & Bienert-Zeit, A. (2019). Paranasal sinus cysts in the horse: Complications related to their presence and surgical treatment in

- 37 cases. *Equine Veterinary Journal*, 51(1), 57–63.
- Huang, Z., Xu, H., Xiao, N., Li, Y., Dong, Y., Li, Y., & Zhou, B. (2019). Predictive significance of radiographic density of sinus opacity and bone thickness in unilateral maxillary sinus mycetoma. *ORL*, 81(2–3), 111–120.
- Idugboe, O. J., Otoghile, B., Musa, I. O., & Adeosun, A. A. (2018). Chronic rhinosinusitis: the correlation between symptom severity score and findings on plain radiographs of the paranasal sinuses. *International Journal of Otorhinolaryngology and Head and Neck Surgery*, 4(1), 5.
- Jeon, Y., Lee, K., Sunwoo, L., Choi, D., Oh, D. Y., Lee, K. J., Kim, Y., Kim, J.-W., Cho, S. J., & Baik, S. H. (2021). Deep learning for diagnosis of paranasal sinusitis using multi-view radiographs. *Diagnostics*, 11(2), 250.
- Kim, H.-G., Lee, K. M., Kim, E. J., & San Lee, J. (2019). Improvement diagnostic accuracy of sinusitis recognition in paranasal sinus X-ray using multiple deep learning models. *Quantitative Imaging in Medicine and Surgery*, 9(6), 942.
- Kim, Y., Lee, K. J., Sunwoo, L., Choi, D., Nam, C.-M., Cho, J., Kim, J., Bae, Y. J., Yoo, R.-E., & Choi, B. S. (2019). Deep learning in diagnosis of maxillary sinusitis using conventional radiography. *Investigative Radiology*, 54(1), 7–15.
- Kuwana, R., Arijji, Y., Fukuda, M., Kise, Y., Nozawa, M., Kuwada, C., Muramatsu, C., Katsumata, A., Fujita, H., & Arijji, E. (2021). Performance of deep learning object detection technology in the detection and diagnosis of maxillary sinus lesions on panoramic radiographs. *Dentomaxillofacial Radiology*, 50(1), 20200171.
- Lim, S.-H., Kim, J. H., Kim, Y. J., Cho, M. Y., Jung, J. U., Ha, R., Jung, J. H., Kim, S. T., & Kim, K. G. (2022). Aux-MVNet: Auxiliary Classifier-Based Multi-View Convolutional Neural Network for Maxillary Sinusitis Diagnosis on Paranasal Sinuses View. *Diagnostics*, 12(3), 736.
- Little, R. E., Long, C. M., Loehrl, T. A., & Poetker, D. M. (2018). Odontogenic sinusitis: A review of the current literature. *Laryngoscope Investigative Otolaryngology*, 3(2), 110–114.
- Mori, M., Arijji, Y., Katsumata, A., Kawai, T., Araki, K., Kobayashi, K., & Arijji, E. (2021). A deep transfer learning approach for the detection and diagnosis of maxillary sinusitis on panoramic radiographs. *Odontology*, 109(4), 941–948.
- Murata, M., Arijji, Y., Ohashi, Y., Kawai, T., Fukuda, M., Funakoshi, T., Kise, Y., Nozawa, M., Katsumata, A., & Fujita, H. (2019). Deep-learning classification using convolutional neural network for evaluation of maxillary sinusitis on panoramic radiography. *Oral Radiology*, 35(3), 301–307.
- Serindere, G., & Aktuna Belgin, C. (2020). An evaluation of the relationship between maxillary sinus anterior wall depression and maxillary sinus opacity by computed tomography and panoramic radiography. *Oral Radiology*, 36(4), 383–388.
- Sheikh, N. N., Ashwinirani, S. R., Suragimath, G., & Kumar, K. M. S. (2018). Evaluation of gender based on the size of maxillary sinus and frontal sinus using paranasal sinus view radiographs in Maharashtra population, India. *Journal of Oral Research and Review*, 10(2), 57.
- Shrestha, M. K., Ghartimagar, D., Ghosh, A., & Jhunjhunwala, A. K. (2020). Sensitivity of sinus radiography compared to computed tomogram: a descriptive cross-sectional study from western region of Nepal. *JNMA: Journal of the Nepal Medical Association*, 58(224), 214.
- Starkey, J. L., & Mortman, R. E. (2019). Treatment of maxillary sinusitis of odontogenic origin: a case series. *Compendium*, 40(8).
- Terlemez, A., Tassoker, M., Kizilcakaya, M., & Gulec, M. (2019). Comparison of cone-beam computed tomography and panoramic radiography in the evaluation of maxillary sinus pathology related to maxillary posterior teeth: Do apical lesions increase the risk of maxillary sinus pathology? *Imaging Science in Dentistry*, 49(2), 115–122.
- Zhou, W., Wang, F., Magic, M., Zhuang, M., Sun, J., & Wu, Y. (2021). The effect of anatomy on osteogenesis after maxillary sinus floor augmentation: a radiographic and histological analysis. *Clinical Oral Investigations*, 25(9), 5197–5204.